

# Pecto-intercostal Fascial Block for Acute Poststernotomy Pain: A Case Report

Victor Liu, MD,\* Edward R. Mariano, MD, MAS,†‡ and Christopher Prabhakar, MD, FRCPC\*§

Sternotomy pain is a common complication after cardiac surgery. We present a 77-year-old patient with severe acute sternal pain after coronary artery bypass graft surgery who was successfully treated with a novel peripheral regional anesthetic technique, the pecto-intercostal fascial block. This interfascial plane block may represent an effective regional anesthetic component of a multimodal analgesic strategy for cardiac surgery patients who suffer from significant pain after a median sternotomy and are typically anticoagulated. (A&A Practice. 2018;10:319–22.)

Poststernotomy pain is a common complication after coronary artery bypass graft (CABG) surgery with severe pain occurring in 49% of patients at rest.<sup>1</sup> In addition to decreased patient satisfaction, poststernotomy pain is associated with adverse postoperative events, such as delirium, hypertension, tachycardia, arrhythmias, respiratory complications, and persistent postsurgical pain.<sup>2,3</sup> Common treatments include opioids, nonsteroidal anti-inflammatory drugs, and infrequently neuraxial or peripheral regional analgesic techniques. Although neuraxial analgesia can reduce the use of opioids<sup>4,5</sup> and their associated adverse effects, such as respiratory depression, nausea, and delirium, there are real concerns related to block failure, sympathectomy-induced hypotension, and devastating (albeit rare) consequences such as epidural hematoma or infection. A peripheral regional analgesia technique may be advantageous in this patient population.

The pecto-intercostal fascial block (PIFB) was recently described by de la Torre et al<sup>6</sup> for anesthesia during breast surgery. Local anesthetic is infiltrated into the interfascial plane between pectoralis major and the intercostal muscles lateral to the sternum to anesthetize the anterior cutaneous branches of the intercostal nerves (Figure 1). We present the application of bilateral PIFB in a patient with severe sternotomy pain after CABG surgery. The patient provided written permission for publication of this report.

## CASE DESCRIPTION

A 77-year-old, 68-kg man was transferred to a tertiary-care hospital for CABG surgery after suffering a non-ST

segment–elevation myocardial infarction and presenting to a community hospital. His comorbidities included known coronary artery disease, paroxysmal atrial fibrillation, pulmonary fibrosis, chronic lymphocytic leukemia, chronic kidney disease, hiatal hernia, and anxiety. His medications were aspirin, rosuvastatin, and metoprolol. He did not have any preexisting chronic pain syndromes. General anesthesia was induced with intravenous midazolam (5 mg), ketamine (40 mg), morphine (20 mg), sufentanil (50 µg), and propofol (70 mg) followed by rocuronium (100 mg) to facilitate endotracheal intubation. Anesthesia was maintained with sevoflurane and intermittent boluses of opioids (10 mg of morphine and 50 µg of sufentanil throughout the case). CABG surgery with full intravenous heparinization proceeded uneventfully, including a left internal thoracic artery graft to the mid left anterior descending artery and saphenous vein graft to the first obtuse marginal artery. After surgery, the patient was sedated with a propofol infusion and transferred to the cardiac surgical intensive care unit (ICU). After 2 hours, sedation was discontinued, and the endotracheal tube was uneventfully removed. For the treatment of pain and anxiety, 2.2 mg of intravenous hydromorphone (0.4 mg every 15–20 minutes) and 1 mg of midazolam were administered in the first 6 hours. The patient continued to complain of severe pain at his midsternum without ST changes, and exhibited objective pain signs such as restlessness, foot-tapping, tachypnea, and hypertension (blood pressure, 180/80 mm Hg) requiring 10 mg of intravenous hydralazine. The patient developed rapid atrial fibrillation that was treated with intravenous amiodarone (150 mg IV bolus followed by 1 mg/min infusion). Due to the acute onset of the arrhythmia and immediate postoperative status, anticoagulation was not initiated.

Analgesia continued to be inadequate after administration of 15 mg of intravenous ketorolac so the regional anesthesia service was consulted. A detailed pain history was taken, and the patient localized his most severe pain along the sternum with no other significant sources of pain (eg, sites of saphenous vein harvest and chest tube placements). He would not provide a numeric rating scale (NRS) score for his pain but would have rated “severe” on a nonverbal scale.<sup>7</sup> He was interested in hearing about the PIFB offered by the regional anesthesia service, lucid enough to have a discussion of risks and benefits, and documented as having a Richmond Agitation-Sedation Scale score of –1 to +2. A shared decision with the patient and the intensivist was made to proceed.

From the \*Department of Anesthesiology, Pharmacology & Therapeutics, The University of British Columbia, Vancouver, British Columbia, Canada; †Department of Anesthesiology, Perioperative and Pain Medicine, Stanford University School of Medicine, Stanford, California; ‡Anesthesiology and Perioperative Care Service, Veterans Affairs Palo Alto Health Care System, Palo Alto, California; and §Department of Anesthesiology, St. Paul's Hospital, Providence Health Care, Vancouver, British Columbia, Canada.

Accepted for publication November 16, 2017.

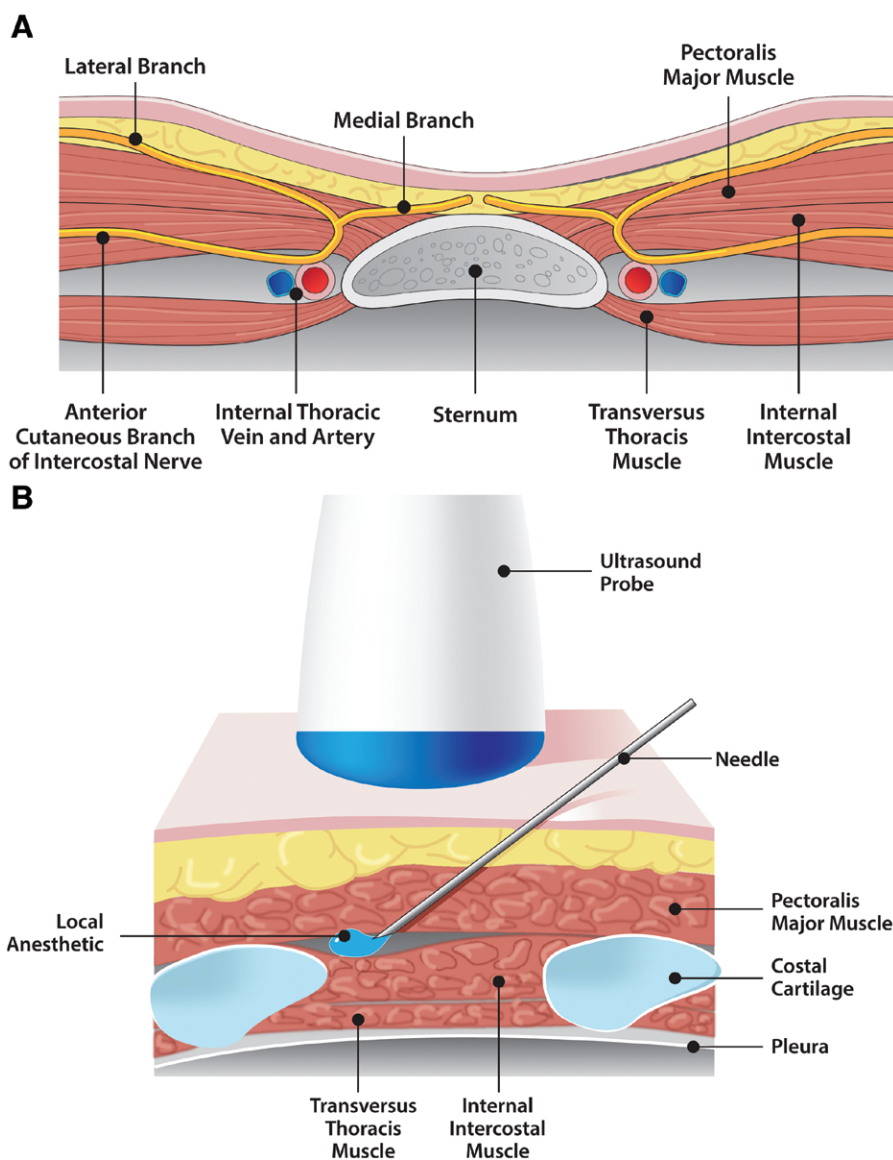
Funding: None.

Conflicts of Interest: See Disclosures at the end of the article.

Supplemental digital content is available for this article. Direct URL citations appear in the printed text and are provided in the HTML and PDF versions of this article on the journal's website ([www.cases-anesthesia-analgesia.org](http://www.cases-anesthesia-analgesia.org)).

Address correspondence to Christopher Prabhakar, MD, FRCPC, Department of Anesthesiology, St. Paul's Hospital, 1081 Burrard St, Vancouver, BC V6Z 1Y6 Canada. Address e-mail to [christopher.prabhakar@gmail.com](mailto:christopher.prabhakar@gmail.com).

Copyright © 2017 International Anesthesia Research Society  
DOI: 10.1213/XAA.0000000000000697



**Figure 1.** Pecto-intercostal fascial plane block. A, Illustration of transverse section of anterior chest. B, Illustration of parasagittal section lateral to sternum and local infiltration between pectoralis major and internal intercostal muscles.

The patient was placed in a supine position, and a high-frequency linear ultrasound probe (GE LOGIQe, GE Healthcare, Chicago, IL) was placed in a parasagittal plane 3 cm lateral from the midsternum. The pectoralis major muscle, internal intercostal muscle (IIM), ribs, and pleura were identified (Figure 2). A 22-gauge, 80-mm, echogenic needle (Pajunk, Geizingen, Germany) was inserted in-plane from caudal to cephalad until the tip was positioned between pectoralis major muscle and IIM, and ideal positioning was confirmed with fluid spread in the plane between these muscles (Supplemental Digital Content, Video 1, <http://links.lww.com/AACR/A151>). The needle was initially positioned superficial to the T5–6 rib space and repositioned in a cephalad direction to target each rib space up to the T1–2 rib space. A total of 3 needle insertions were performed on each side to cover the 5 interspaces. A total of 38 mL of 0.25% ropivacaine with 3.8 mg of dexamethasone was administered (20 and 18 mL on left and right sides, respectively). No immediate or delayed complications occurred.

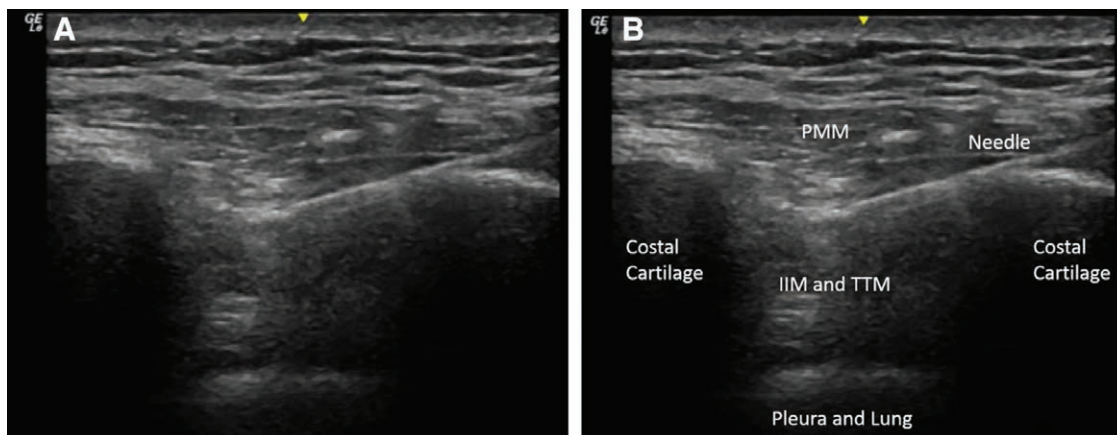
The patient reported almost immediate pain relief (NRS score 1–2/10). His intravenous opioid requirement

decreased from 2.2 mg of intravenous hydromorphone and 25 µg of fentanyl during the prior 6 hours to 0.8 mg of intravenous hydromorphone and 50 µg of fentanyl over the next 13 hours postblock. No further antihypertensives were required. During the 2-day stay in the ICU, his NRS scores remained 1–3/10. Pain was managed with oral opioids only, and no rebound pain was reported after block resolution.

The patient was asked a week after his surgery to report his experience. He remembered having severe sternal pain right after extubation and being unable to provide a NRS pain score. It was only after the block was performed that he felt clear headed enough to rate his pain appropriately. The incision had healed well with no signs of infection, and the patient was discharged home 9 days after surgery. There were no adverse effects from the block.

## DISCUSSION

We report the successful use of PIFB to treat acute post-sternotomy pain in a patient who underwent CABG surgery with internal thoracic artery dissection. The PIFB can



**Figure 2.** Ultrasound image of the intercostal space lateral to sternum in the sagittal orientation. A, Image without identifying labels. B, Image with identifying labels. IIM indicates internal intercostal muscle; TTM, transversus thoracis muscle; PMM, pectoralis majoris muscle.

provide immediate and sustained pain relief, reduction in opioid requirement, and elimination of pain-induced hypertension. There are a few reports describing this block for breast analgesia<sup>6,8</sup> and sternal fracture pain,<sup>9,10</sup> and to facilitate ventilator weaning in ICU patients with rib cage pain,<sup>11</sup> but no previously published articles showing the utility of PIFB for poststernotomy pain treatment.

Poststernotomy pain is common after cardiac surgery. Risk factors associated with increased severity and prevalence include female gender, young age, and internal thoracic artery dissection.<sup>2,3</sup> The incidence of persistent pain after cardiac surgery may be as high as 31% at 1 year and occurs more frequently in patients who experienced moderate to severe acute postsurgical pain.<sup>1</sup> Regional analgesia, when performed safely under ultrasound guidance and without the risk of epidural hematoma, offers many benefits in the cardiac surgery population that may include reduced opioid consumption, improved pain control and respiratory mechanics, and improved patient satisfaction.<sup>4,5</sup>

The only other descriptions of PIFB for poststernotomy pain can be found in an abstract presentation at a national regional anesthesiology meeting<sup>12</sup> and in a letter to the editor that reports performance of the block for preventive analgesia before surgical incision.<sup>13</sup> However, other similar block techniques are described for analgesia of the medial chest with confusing nomenclature.<sup>4,6,8-15</sup> The PIFB has also been called a “subpectoral interfascial plane block,”<sup>10</sup> a component of a “thoracic interfascial nerve block,”<sup>8</sup> and a “parasternal Pecs block.”<sup>13</sup> All block techniques in this region aim to anesthetize the anterior cutaneous branches of the intercostal nerves. Ueshima and Kitamura<sup>14</sup> describe the transversus thoracis plane block in which local anesthetic is placed in the plane between transversus thoracis and IIMs that has been used for breast surgery. Thomas et al<sup>9</sup> describe a “parasternal block” that is essentially the transversus thoracis plane block used to treat pain from a sternal fracture. Both techniques are deeper than the PIFB we describe, thus potentially increasing risk and making needle visualization more difficult. The “parasternal intercostal block” involves blind local anesthetic injection into the intercostal muscles.<sup>4,5,15,16</sup> This landmark-based approach, while potentially appealing, carries a risk of vascular or pleural injury that may be avoided with the more superficial

ultrasound-guided PIFB. The PIFB as described by us requires 6 injections compared to 14 injections required for the parasternal block technique.<sup>5</sup>

Characteristics of the PIFB allows clinicians to perform this block in those patients who will benefit the most (eg, those with sternal pain poorly controlled with opioids) but who may be difficult to identify preoperatively. There are very limited data on the safety profile of the PIFB or effectiveness compared to other regional analgesic techniques; however, it is arguably less invasive than thoracic epidural or paravertebral analgesia with no risk of serious complications like epidural or spinal hematoma in this patient population that is routinely anticoagulated during surgery.

This case report was limited by the fact that pain scores were difficult to obtain from the patient during the acute period before the block, which we attributed to a combination of severe pain and intravenous sedation in the ICU. A nonverbal pain rating and/or sedation scale is more appropriate in this population.<sup>7</sup> To minimize manipulation in the area around the sternal incision, serial assessments of the block were not performed and therefore the block duration is unknown.

In conclusion, the PIFB shows promise as a safe and effective analgesic technique for treatment of sternotomy pain after cardiac surgery, particularly in these patients who are typically anticoagulated. Because this is a relatively new technique, more studies are required to establish the safety profile, indications, effectiveness compared to other nerve blocks, and the optimal dosing of local anesthetic. ■■

#### ACKNOWLEDGMENT

We would like to thank Kristopher J. Morrow, Medical Illustrator, Office of the Director, Public Affairs Office, VA Palo Alto Health Care System, for designing illustrations for this article.

#### DISCLOSURES

**Name:** Victor Liu, MD.

**Contribution:** This author helped care for the patient, research the references, and write the manuscript.

**Conflicts of Interest:** None.

**Name:** Edward R. Mariano, MD, MAS.

**Contribution:** This author helped extensive editing and rewriting, and provided graphic illustrations.

**Conflicts of Interest:** Dr Mariano has received unrestricted educational program funding paid to his institution from Halyard Health (Alpharetta, GA). This company had no input into any aspect of manuscript preparation.

**Name:** Christopher Prabhakar, MD, FRCPC.

**Contribution:** This author helped care for the patient, and edit the manuscript.

**Conflicts of Interest:** None.

**This manuscript was handled by:** Hans-Joachim Priebe, MD, FRCA, FCAI.

## REFERENCES

1. Lahtinen P, Kokki H, Hynynen M. Pain after cardiac surgery: a prospective cohort study of 1-year incidence and intensity. *Anesthesiology*. 2006;105:794–800.
2. Huang AP, Sakata RK. Pain after sternotomy - review. *Braz J Anesthesiol*. 2016;66:395–401.
3. Mazzeffi M, Khelemsky Y. Poststernotomy pain: a clinical review. *J Cardiothorac Vasc Anesth*. 2011;25:1163–1178.
4. Barr AM, Tutungi E, Almeida AA. Parasternal intercostal block with ropivacaine for pain management after cardiac surgery: a double-blind, randomized, controlled trial. *J Cardiothorac Vasc Anesth*. 2007;21:547–553.
5. McDonald SB, Jacobsohn E, Kopacz DJ, et al. Parasternal block and local anesthetic infiltration with levobupivacaine after cardiac surgery with desflurane: the effect on postoperative pain, pulmonary function, and tracheal extubation times. *Anesth Analg*. 2005;100:25–32.
6. de la Torre, Patricia Alfaro, García PD, Alvarez SL, Miguel FJG, Pérez MF. A novel ultrasound-guided block: a promising alternative for breast analgesia. *Aesthet Surg J*. 2014;34:198–200.
7. Polomano RC, Galloway KT, Kent ML, et al. Psychometric testing of the Defense and Veterans Pain Rating Scale (DVPRS): a new pain scale for military population. *Pain Med*. 2016;17:1505–1519.
8. Hong B, Yoon SH, Youn AM, Kim BJ, Song S, Yoon Y. Thoracic interfascial nerve block for breast surgery in a pregnant woman: a case report. *Korean J Anesthesiol*. 2017;70:209–212.
9. Thomas KP, Sainudeen S, Jose S, Nadhari MY, Macaire PB. Ultrasound-guided parasternal block allows optimal pain relief and ventilation improvement after a sternal fracture. *Pain Ther*. 2016;5:115–122.
10. Raza I, Narayanan M, Venkataraju A, Ciocarlan A. Bilateral subpectoral interfascial plane catheters for analgesia for sternal fractures: a case report. *Reg Anesth Pain Med*. 2016;41:607–609.
11. López-Matamala B, Fajardo M, Estébanez-Montiel B, Blancas R, Alfaro P, Chana M. A new thoracic interfascial plane block as anesthesia for difficult weaning due to ribcage pain in critically ill patients. *Med Intensiva*. 2014;38:463–465.
12. Warner L, Ritter M. Abstract 3842: bilateral pecto-intercostal fascial plane block for acute relief of post-sternotomy pain. ASRA 42nd Annual Regional Anesthesiology and Acute Pain Medicine Meeting, April 6–8, 2017, San Francisco, CA. *Reg Anesth Pain Med*. 2017; 42: 802–818.
13. Del Buono R, Costa F, Agrò FE. Parasternal, pecto-intercostal, pecs, and transverse thoracic muscle plane blocks: a rose by any other name would smell as sweet. *Reg Anesth Pain Med*. 2016;41:791–792.
14. Ueshima H, Kitamura A. Blocking of multiple anterior branches of intercostal nerves (Th2-6) using a transversus thoracic muscle plane block. *Reg Anesth Pain Med*. 2015;40:388.
15. Chaudhary V, Chauhan S, Choudhury M, Kiran U, Vasdev S, Talwar S. Parasternal intercostal block with ropivacaine for postoperative analgesia in pediatric patients undergoing cardiac surgery: a double-blind, randomized, controlled study. *J Cardiothorac Vasc Anesth*. 2012;26:439–442.
16. Saini K, Chauhan S, Kiran U, Bisoi AK, Choudhury M, Hasija S. Comparison of parasternal intercostal block using ropivacaine or bupivacaine for postoperative analgesia in patients undergoing cardiac surgery. *World J Cardiovasc Surg*. 2015;05:49.